

# Total reconstruction of the vesico-urethral junction

Ashutosh Tewari, Jay Jhaveri, Sandhya Rao, Rajiv Yadav, Georg Bartsch\*, Alexis Te, Edward Ioffe, Miguel Pineda, Senthil Mudaliar, Lang Nguyen, John Libertino† and Darracott Vaughan

Departments of Urology, Program in Robotic Surgery, New York Presbyterian Hospital – Weill Cornell Medical College, NY, †Lahey Clinic Medical Center, Burlington, MA, USA, and \*Department of Urology, Innsbruck Medical University, Innsbruck, Austria

Accepted for publication 21 September 2007

Study Type – Therapy (case series)  
Level of Evidence 4

## OBJECTIVE

We describe a novel technique of total vesico-urethral reconstruction, which combines the tactics of previous surgeons, and compare the outcome of our innovative changes for return to early continence with prostatectomies with no or partial reconstruction of the vesico-urethral junction.

## PATIENTS AND METHODS

Between 1 January 2005 and 5 June 2007 a cohort of 700 patients undergoing robotic radical prostatectomy were prospectively evaluated. Patients in 2005 (214) served as a control group, they received no additional methods to provide support to the vesico-urethral junction; a standard anastomosis was made. Patients in 2006 (304) received an anterior reconstruction only, to provide

additional vesico-urethral anastomotic support. Patients in 2007 (182) received the total reconstructive procedure, which included an anterior reconstruction and posterior reconstruction. Outcome data were collected using standardized health-related quality-of-life measures, which included the Expanded Prostate Cancer Index Composite survey, International Prostate Symptom Score, International Index of Erectile Function, and then re-verified by telephone interview with a standardized questionnaire. The follow-up intervals were 1, 6, 12, 24 and 52 weeks. Continence was defined as no pad usage or one small liner used for security purposes only. Baseline variables were also collected.

## RESULTS

The percentage of patients who had achieved continence in the control group were: 13%, 35%, 50%, 62% and 82% at the 1-, 6-, 12-, 24- and 52-week follow-up, respectively. The percentage of patients who had achieved continence in the anterior reconstruction

group were 27%, 59%, 77%, 86%, and 91%, respectively. The total reconstruction group had continence rates of 38%, 83%, 91%, and 97% at 1, 6, 12, and 24 weeks, respectively. At all the follow-up intervals the continence rate was significantly less in the control group than in the anterior reconstruction group and the total reconstruction group ( $P < 0.01$ ).

## CONCLUSIONS

The total reconstruction procedure is a safe and effective way to achieve an early return to continence. No adverse effects have been observed because of its employment and our data validates that it does provide a statistically significant early return to continence compared with no reconstructive efforts or with only anterior reconstructive efforts.

## KEYWORDS

continence, prostatectomy, reconstruction, outcome, robotic

## INTRODUCTION

Urinary incontinence can significantly reduce quality of life (QoL) and raise the cost of care after surgical treatment of prostate cancer. Several surgical modifications have been proposed to minimize the incidence of urinary incontinence after radical prostatectomy (RP). These include reconstruction of the bladder neck [1], approximation of anterior supporting structures [2,3], creation of posterior support to urethra [4,5], plication of detrusor flaps on the posterior aspect [6] and variations of suspension sutures [2–6]. Published data varies when discussing the time to return of continence after RP, therefore there is a need for further modifications that can minimize duration of

incontinence. We have previously described our own technique, which involves preserving puboprostatic ligaments and reconstructing the anterior urethral supporting structures by suturing arcus tendineus and puboprostatic ligaments to the bladder neck [7]. This effort resulted in significant improvement in urinary continence rates in comparison with the patients who did not undergo this modification [3]. However, we think that even better results can still be attained.

Recently, we became aware of two new techniques that hasten recovery of continence by providing crucial compression at the bladder neck, and by providing firm posterior support to the urethral sphincter. These are the detrusor reinforcing technique

developed by Dr Pagano (personal communication by Dr Libertino) [6] and the posterior suture to prevent distal migration of central tendon. (personal communication by Dr Bartsch, the 'Rocco suture') [4,5].

We have since incorporated these two modifications into our technique, supporting the posterior bladder neck [4–6] and using a suture to pull the distal Denonvilliers' fascia towards the bladder base [4,5] in the cephalic direction. As a result, our patients now possess both anterior and posterior support of the urethral continence mechanism. In addition, these techniques also reduce tension on the vesico-urethral anastomosis and prevent disruption in the event of a pelvic haematoma [4–7].

We implemented these modifications at the beginning of January 2007 and have since noted significant improvement in the return of early continence (when compared with our own control patients who were operated on with conventional techniques). Presented herein are the results of a prospective study that involved third party evaluation of urinary continence in 182 consecutive patients undergoing robotic RP with total anatomic reconstruction with anterior and posterior support. To reflect the development of our techniques and the impact of each surgical modification on the return of continence, we also include all patients (700) operated on by a single surgeon (A.T.) since January 2005.

## PATIENTS AND METHODS

We report a prospective study involving a cohort of patients undergoing robotic RP between 1 January 2005 and 5 June 2007. Outcome data were collected under an Institutional Review Board approved protocol. In 2005, we did not use any special measures for early continence. In 2006 we began to use anterior reconstruction and in 2007 we added posterior reconstruction resulting in a technique we term 'Total Anatomic Reconstruction'. Because the primary surgeon had performed close to 1000 robotic RPs before embarking on these modifications, his early learning curve was not a concern. Accordingly, we were uniquely able to draw conclusions about the impact of each technical innovation on the return of continence.

Patients in our programme undergo a standardized preoperative evaluation that includes serum PSA measurement, systematic prostate biopsy, DRE, comorbidity estimation and calculation of body mass index. In most cases, we obtained endorectal MRI and in select cases (those with a PSA level of >10 ng/mL and/or Gleason score  $\geq 7$ , or those with clinical T3 prostate cancer) we also obtained bone scans and CT of the abdomen and pelvis. Baseline urinary symptoms were measured using the IPSS [8] and the Expanded Prostate Cancer Index Composite [8] validated health-related QoL (HRQoL) instruments.

In all, 700 patients underwent robotic RP by a single surgeon (A.T.) over 30 months at our institution. Of these, the 182 most recent patients underwent surgeries that included the above-described modifications while the

earlier 518 patients served as historical controls for outcome comparison. (No reconstruction whatsoever was attempted in the 214 of these patients, while anterior reconstruction alone was performed in 304).

## TOTAL ANATOMIC RECONSTRUCTION TECHNIQUE FOR CONTINENCE PRESERVATION

We take a rather simplistic approach to continence preservation based on visual appreciation of functional anatomy. In other words, the governing principle behind our technique is that 'at the end of procedure, the closer we are to pre-surgical anatomy, the better the functional results would be' (Tewari). Adhering to this principle, we avoid any tissue that is not prostatic in nature, and we avoid disrupting the anatomy unnecessarily as we reconstruct it to most closely resemble its preoperative character (Fig. 1 shows the normal anatomy).

Our continence preservation technique involves seven key elements: (i) Preservation of puboprostatic ligaments and arcus tendineus; (ii) Creation of a muscular flap behind the bladder neck (to later suture to the distal end of Denonvilliers' fascia behind the sphincter); (iii) Control of the dorsal venous complex using a puboprostatic ligament sparing suture; (iv) Preparation of a thick and long urethral stump during apical dissection; (v) The 'Pagano principle', reinforcing of the flap behind the bladder neck; (vi) The 'Rocco principle', suturing of the flap to the distal end of Denonvilliers' fascia, close to the urethral stump, to prevent caudal retraction of the central tendon, thus providing posterior support; and (vii) Re-attachment of the arcus tendineus and puboprostatic plate to the bladder neck after anastomosis is completed.

We describe each of the steps in greater detail below:

(i) *Preservation of puboprostatic ligaments and arcus tendineus.* We achieve this goal by making a small (1–2 cm) vertical incision of the endopelvic fascia at the level of the mid-prostate. An attempt is made to incise medially and to leave a 5–10 mm strip of intact endopelvic fascia and arcus tendineus laterally. Distally, the incision stops 5 mm proximal to the apex, and it curves medially under the endopelvic fascia, leaving puboprostatic ligaments intact and attached to the arcus tendineus. This dissection leaves

FIG. 1. Normal anatomy.

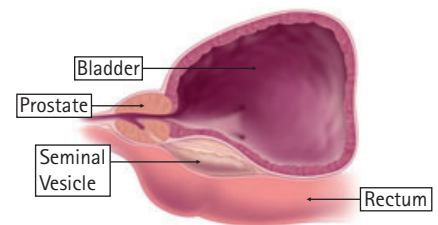
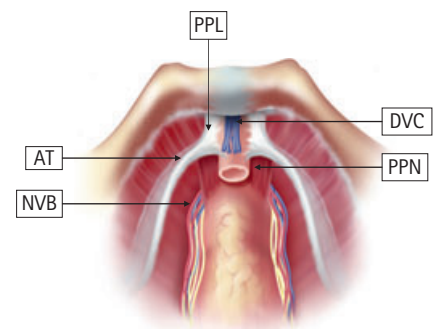


FIG. 2. Preservation of puboprostatic ligaments and arcus tendineus. PPL, puboprostatic ligaments; PPN, puboperinealis; NVB, neurovascular bundle; AT, arcus tendineus; DVC, dorsal vein complex.



an intact triangular plate of fibro-tendinous structure anterior to the urethra, intrinsic rhabdosphincter, dorsal venous complex and puboperinealis muscle. This triangular plate, the 'anterior stabilizing plate for membranous urethra' (Fig. 2), is comprised of puboprostatic ligaments, distal sheet of endopelvic ligaments and arcus tendineus. It supports the critical sphincteric mechanism and provides stability and purchase during compressive action of the muscles.

(ii) *Creation of a muscular flap behind the bladder neck.* We have previously described a vascularized fibromuscular layer, the 'retrotrigonal layer' [9,10], which can be developed to create a flap of tissue behind the bladder neck. Although questions about the origin of this layer remain unresolved [9,10] there is little doubt that it exists and can be used to surgeons' advantage by providing posterior support to the bladder neck (Fig. 3).

(iii) *Control of the dorsal venous complex using a puboprostatic ligament-sparing suture.* As shown in Fig. 4, we use zero polyglactin suture on a CT-1 needle, starting anteriorly,

FIG. 3. Creation of a muscular flap behind the bladder neck. PPL, puboprostatic ligaments; NVB, neurovascular bundle; AT, arcus tendineus; DVC, dorsal vein complex; RTL, retritrigonal layer.

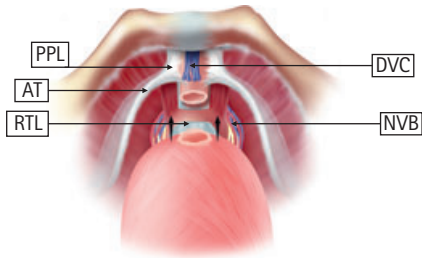


FIG. 4. Control of the dorsal venous complex using a puboprostatic ligament-sparing suture. PPL, puboprostatic ligaments; PPN, puboperinealis; DVC, dorsal vein complex; AT, arcus tendineus.

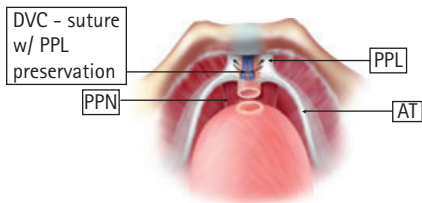


FIG. 5. Prepare a thick and long urethral stump during apical dissection. PPL, puboprostatic ligaments; PPN, puboperinealis; DVC, dorsal vein complex; AT, arcus tendineus.

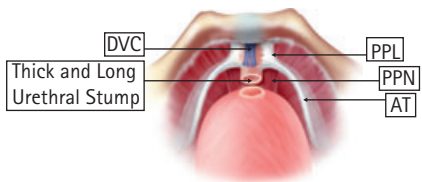


FIG. 6. The 'Pagano principle', reinforce the flap behind the bladder neck [6]. RTL, retritrigonal layer, RS, rhabdosphincter; DNVF, Denonvilliers' fascia.

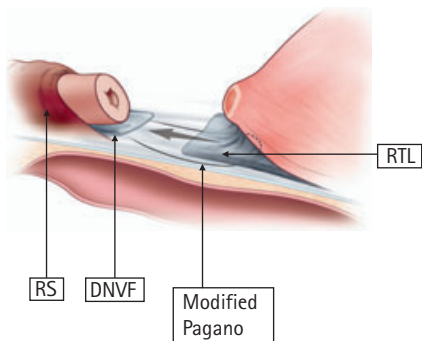
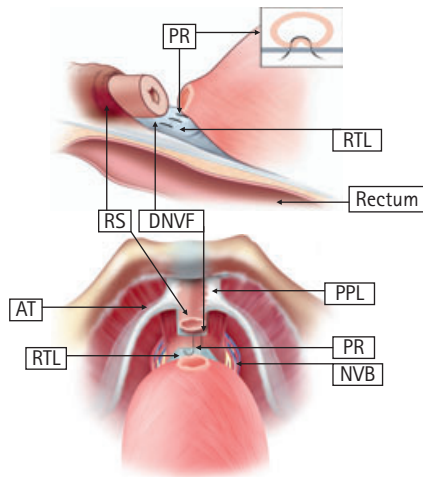


FIG. 7. The 'Rocco principle', suture the flap to the distal end of Denonvilliers' fascia close to the urethral stump [4, 5]. PR, posterior reconstruction; RTL, retritrigonal layer, RS, rhabdosphincter; DNVF, Denonvilliers' fascia; AT, arcus tendineus; PPL, puboprostatic ligaments; NVB, neurovascular bundle.



going deeper to the medial edge of right puboprostatic ligament, and then bringing the needle to the right side sliding under the right puboprostatic ligaments. Next, we pass the needle deeper, from right to left, to the dorsal venous complex, and we avoid going through the urethra and distal aspect of neurovascular exit from the pelvis. Suture is then passed from left to right under the left puboprostatic ligaments so that it emerges anteriorly close to its tail. It is now tightened with a slip-knot. This suture exclusively controls the dorsal venous complex and spares the ligaments, sphincter and terminal neurovascular branches from injury.

(iv) Preparation of a thick and long urethral stump during apical dissection (Fig. 5). This step of surgery is most critical for the return of urinary continence. Apical dissection is one of the most challenging components of RP as the margin of error is very small and stakes in terms of positive margin, continence and sexual function are very high. The conservative and familiar approach involves several key components. Stay outside the capsule and prostatic apex with a 1–2 mm safety margin. Secure the dorsal venous complex with the puboprostatic sparing suture (described above). Obtain a relatively bloodless field. Incise the tissue sharply to avoid charring. And finally, do not dissect the periurethral tissue to obtain a long cylindrical

stump, as this long stump may be just mucosa and some muscle fibres with missing or damaged critical sphincter complex. We have previously described a method for bimanual pinching or palpation technique to get a precise demarcation of the urethro-apical junction [11]. This manoeuvre allows compression of the superficial dorsal venous complex, and it helps in obtaining a thick and long urethral stump with intact periurethral sphincteric complex, supporting fascia, muscles and ligaments.

(v) The 'Pagano Principle', reinforcing of the flap behind the bladder neck (Fig. 6). This is an important concept propagated by Dr Pagano and we were fortunate to learn about it from Dr Libertino during a visit to our programme (personal communication). The Classical Pagano suture involves midline suturing of right and left detrusor flaps behind the bladder neck to create a thick muscular bladder neck [6]. We use this step with some modification, using a single (3/0 polyglactin on an RB-1 needle) suture (as described later) that incorporates the retritrigonal flap into the posterior bladder neck and cinches it down to the distal Denonvilliers layer. (Rocco concept below).

(vi) The 'Rocco Principle', suturing of the flap to the distal end of Denonvilliers' fascia (Fig. 7). Dr Rocco recently described an innovative technique to reconstruct the rhabdosphincter and Denonvilliers fascia. His technique provides firm support to the urethral sphincter and avoids caudal retraction of the posterior median raphe and perineal body [4,5]. Dr Rocco uses two sutures, one to reconstruct Denonvilliers' fascia to the sphincter and a second to anchor the posterior bladder to the Denonvilliers' fascia [4,5]. Contrary to Dr Rocco's original description we do not 'tennis racket' the bladder neck and use the same Pagano suture to reinforce the posterior bladder neck and suture it to distal Denonvilliers' fascia (attached to the posterior sphincter). This better achieves the principles stated by Dr Rocco that posterior reconstruction provides support to the sphincter and avoids downward retraction of the sphincter. We use a single knotted suture (15–23 cm long, 3/0 polyglactin on RB-1 needle) and start at the distal Denonvilliers' fascia (10–20 mm proximal to the sphincter) to avoid injury to the nerves. We next reinforce the posterior bladder neck by including retritrigonal layer [9–11]. We take two distal and two proximal

bites and cinch it down near the urethra. It takes about 1–2 min to execute this procedure, thus achieving the aims of Dr Rocco and Dr Pagano's principles in one step. A running watertight anastomosis is made next, using a previously described technique.

(vii) *Re-attachment of the arcus tendineus and puboprostatic plate to the bladder neck* (Fig. 8). This step involves using a single knotted suture (3/0 polyglactin on an RB-1 needle) to approximate remaining arcus tendineus and distal triangular plate to the bladder neck. Care is taken to avoid both piercing of any accessory vessels travelling near the arcus tendineus and excessive tightening of the suture [3]. This step also takes 1–2 min and allows for anterior stabilization of the vesico-urethral complex.

Intraoperative digital video recordings were made (Sony™ DSR45A DVCAM Compact Digital VTR with 2.5" LCD; Sony Corporation of America, New York City, NY, USA). Video-clips were stored on miniature digital video-tapes and on digital storage devices, and nonlinear editing and review of the media was done using a Macintosh computer and Final Cut Pro™ Software (Apple Computer, Inc., Cupertino, CA, USA).

All patients were followed on a standard clinical pathway, and barring complications, they were discharged the morning after RP. All patients were sent home with an indwelling Foley catheter; that was left *in situ* for 7 days.

Preoperative information was collected on a custom-designed data-sheet that included age, previous abdominal surgery, comorbidity, body mass index (BMI), serum PSA level, biopsy Gleason score and clinical stage. Variables recorded during and after surgery included the details of each surgical procedure, entered on a comprehensive data-collection sheet completed by a third party (recording the times of entry into the operative room, induction of anaesthesia, and the various steps of the operation). Additional data included blood loss, the postoperative pain score, days of hospitalization, haemoglobin level at discharge and duration of catheterization. Any complication occurring at <30 days after RP was recorded as a perioperative complication. Several patients underwent cystometry before removal of the catheter. We take cystograms when the catheter is

removed <5 days after surgery or when there is reason to suspect urinary leak (high drain output first day after surgery).

The surgical specimens were inked and processed for histopathological analysis. Margins were considered positive if there was tumour present at the inked margin. The PSA level after RP was recorded during each of three monthly clinic visits. Biochemical recurrence was defined as two successive PSA levels of >0.02 ng/mL.

Functional data were collected with validated instruments and re-checked by a third-party telephone interviewer who asked the patients about preoperative sexual function, ability to obtain an erection, recent sexual intercourse (within 4 weeks), use of sildenafil and the number of pads or liners used to manage urinary incontinence. Continence was defined as using no pads or a liner for security reasons only.

The outcome of primary interest in the present study was the median number of days required to achieve total continence. Secondary outcomes included the percentage of men continent at 1, 6, 12, 24, and 52 weeks after RP.

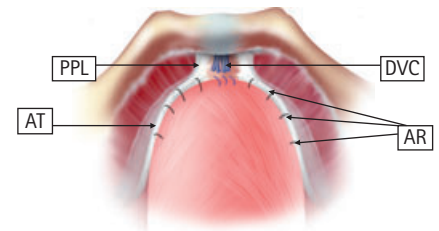
Data were analysed using Fisher's exact test and chi-square analysis, allowing comparisons of groups with nominal variables while continuous variables were compared using ANOVAS.

## RESULTS

Table 1 summarizes the baseline characteristics of our patient cohort, which included 700 patients who underwent robotic RP over 30 months. The patients were aged 61–64 years with a trend towards relatively younger patients more recently. The BMI was 24–28 kg/m<sup>2</sup> ( $P = NS$ ) and the prostate volume was 50–57 mL ( $P < 0.05$  for controls). All other demographic and oncological variables were comparable between the three groups. The mean duration of follow-up was lowest for the total reconstruction group and highest for the control group.

Table 2 summarizes the operative variables in the three patient groups. Notably, the times for the console duration were comparable across the three groups, and it took minimal operative times to complete these

FIG. 8. Re-attach the arcus tendineus and puboprostatic plate to the bladder neck once anastomosis is completed. PPL, puboprostatic ligaments; AT, arcus tendineus; DVC, dorsal vein complex; AR, anterior reconstruction.



reconstructions. The estimated blood loss, duration of catheterization, and urinary leaks were also comparable across the three groups.

Table 3 shows that continence outcomes were far superior for anterior and total reconstructions at 1, 6, 12 and 24 weeks after surgery. Patients undergoing total reconstruction had a 97% probability of regaining continence by 6 months after RP. The median time to continence was only 3 weeks for this group of patients (four times faster than the control group where it was 12 weeks). The trends for time to continence recovery are shown in Fig. 9.

Cystograms taken for each of the three groups of patients (Fig. 10) were assessed to determine the amount of vesico-urethral junction descent. Notably patients that had a total reconstruction had minimal descent of the vesico-urethral junction, and this might play a contributing role in their early return of continence.

## DISCUSSION

The present technique provides critical anterior and posterior support to the urethral sphincter mechanism, resulting in the early return of urinary continence. Moreover, it does not result in increased operating durations or any untoward outcomes.

Our continence preservation technique involves seven key elements: (i) preservation of puboprostatic ligaments and arcus tendineus; (ii) creation of a muscular flap behind the bladder neck (to be later sutured to the distal end of Denonvilliers' fascia behind the sphincter); (iii) control the dorsal venous complex using a puboprostatic ligament

TABLE 1 Baseline characteristics

Variable	Group			P
	Control	Anterior reconstruction	Total reconstruction	
N	214	304	182	
Age, years	64.32	62.84	61.21	<0.05
Body mass index, kg/m <sup>2</sup>	28.77	28.74	24.98	NS
Prostate volume, mL	57.12	50.73	50.53	<0.05
IIEF	55.91	58.5	54.25	NS
PSA level, ng/mL	6.02	5.94	5.76	NS
Mean follow-up, weeks	108	54	18	
%:				
Gleason score				
1–6	47.66	28.61	36.26	NS
7 (3 + 4)	40.65	43.09	50.54	
7 (4 + 3)	6.07	11.84	7.14	
8, 9, 10	5.60	6.25	4.94	
Risk group				
Gp 1	32.24	26.60	23.24	NS
Gp 2	31.30	28.32	32.4	
Gp 3	14.01	20.60	23.24	
Gp 4	22.42	24.03	21.08	
Clinical stage				
T1a	0.46	0	0	NS
T1c	74.76	77.63	80.76	
T2	23.83	20.39	16.48	
T3	0.9	1.9	2.7	
Pathological stage				
T2	87.38	82.89	80.28	NS
T3	11.21	12.17	18.77	
T4	0.93	1.31	0.46	
Margin positive rates (T2)	3.8	7	4.8	NS

NS, not significant.

TABLE 2 Operative data

Variable	Group			P
	Control	Anterior reconstruction	Total reconstruction	
Time, min				
Robotic console	120	100	90	<0.5
Posterior reconstruction	NA	NA	2	N/A
Anastomotic	12	10	8	NS
Anterior reconstruction	NA	5	4	NS
Estimated blood loss, mL	150	150	140	NS
In situ catheter duration, week	1	1	<1	NS

NS, not significant; N/A, not applicable.

sparing suture; (iv) preparation of a thick and long urethral stump during apical dissection; (v) application of Pagano's principle, reinforcing the flap behind the bladder neck; (vi) application of Rocco's principle, suturing

the flap to the distal end of Denonvilliers' fascia close to the urethral stump to prevent caudal retraction of the central tendon (thus providing posterior support); and (vii) re-attachment of the arcus tendineus and

puboprostatic plate to the bladder neck once anastomosis is completed.

Our total reconstruction approach is firmly based on the principles of Dr Pagano (personal communication) and Dr Rocco and on our previously described anterior reconstruction technique [2–7]. By smoothly integrating the brilliant innovations of these two Italian surgeons, it provides complete support to the sphincter mechanism and prevents recession of the central tendon. But unlike these two techniques in isolation, our hybrid technique incorporates important anterior reconstruction as well as preservation of puboprostatic ligaments. These additions stabilize the sphincter anteriorly and provide total support; hence the name, 'Total Anatomic Reconstruction'. Our hybrid technique might provide additional theoretical benefits, such as the avoidance of injury to the retro-apical neuroanatomical plexus (crossing posterior nerves near the urethral sphincter) [2–6]. This is because we place our posterior suture farther from those nerves, which is a possibility in classical description of the distal suture [10,11]. We addressed this concern by placing our suture more proximally (1–2 cm) and leaving this critical area untouched.

Despite the great benefits of our total reconstruction technique, and the many patients in which we have implemented it, there are, of course, a few potential flaws in the present study. Although this is a prospective study, our continence preservation technique ultimately developed through two distinct stages, anterior reconstruction, first, followed by combined anterior and posterior reconstruction only later. This was a consequence of the incremental conceptualization of the pathophysiology as well as our late cognizance of helpful advances by other authors [4–11]. As a result, we could not randomize the present study, leaving the possibility that the data were skewed by developments in practice, the gained experience of the surgeon, and/or younger (and healthier) patients in recent years. Nonetheless, these potential confounds strike us as unlikely because we included consecutive patients, the operating surgeon had very extensive experience in robotic RP before embarking on these modifications, and because there were no significant demographic differences between the three cohorts.

TABLE 3 Continence outcomes

Variable	Group		
	Control	Anterior reconstruction*	Total reconstruction†
N	214	304	182
Median time to continence, weeks	12	4	3
% patients with 0 pads at follow-up (weeks)			
1	13.15	27.00	38.37
4-6	35.21	59.00	82.56
12	50.23	76.67	91.30
24	61.97	85.67	97.14
52	82.16	91.28	N/A

N/A, not available. \*At every time point, percentage continence was statistically significantly better ( $P < 0.01$ ) after anterior reconstruction vs control (no reconstruction); †At every time point, percentage continence was statistically significantly better ( $P < 0.01$ ) after total reconstruction vs control (no reconstruction).

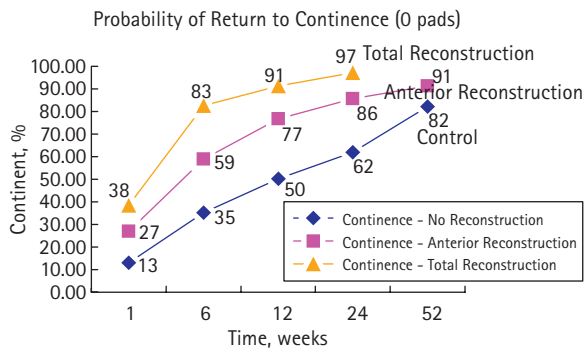


FIG. 9. Probability of return to continence (0 pads).

Furthermore, the large sample size (700 patients) should have attenuated the impact of these biases. Thus, we conclude confidently that this technique affords an earlier and increased probability of continence after robotic RP.

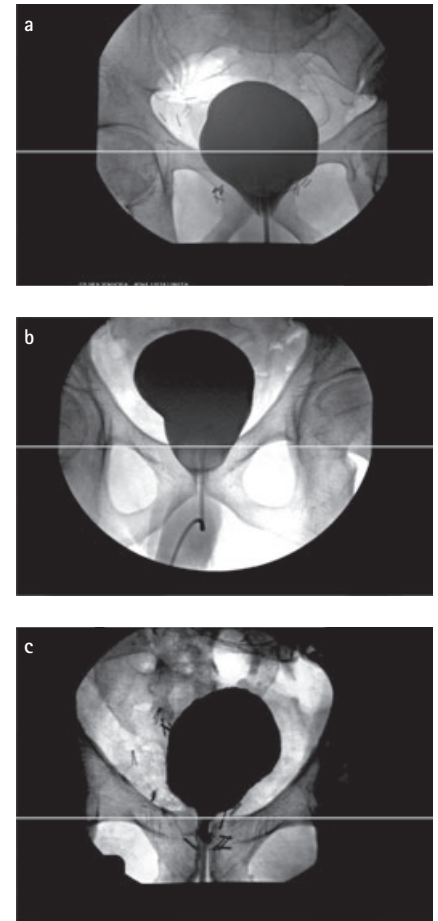
One final issue unresolved by the present study involves the distinct roles of anterior and posterior reconstruction in the positive outcomes that we found. In particular, perhaps greatly improved continence could be attained solely by posterior reconstruction? Indeed, we are contemplating a randomized study to contrast these two techniques but at present, we feel comfortable employing the total reconstruction technique because it not only results in excellent continence, but also provides additional security to the anastomosis in the event of a pelvic haematoma. Anecdotally, it is worth mentioning that this scenario actually took place in our practice recently. The patient had bleeding after coumadin therapy became super therapeutic (for a pre-existing cardiac

valve) but the anastomosis stayed intact, and the patient regained continence at <1 week after the episode.

Moreover, the present results compare favourably to other published reports on the return to continence after the use of one or more restoration techniques. Most of these studies have left the catheter *in situ* for 2–3 weeks, and therefore their earliest evaluation is 4–6 weeks after surgery. By that time, nearly 84% of the patients in the present study were already continent.

In conclusion, we have described a simple, and reproducible technique for supporting urethral continence mechanism by anterior and posterior reconstruction, the 'Total Anatomic Reconstruction' technique. The technique involves the use of two 15 cm running sutures with knots on the end and a small tail, one for posterior and the other for the anterior reconstruction. It is easy and time efficient. Preliminary results are promising, and based on a very large sample size. Future

FIG. 10. Typical cystograms from; (a) Control group with no reconstruction, the distance between the pubic ramus and vesico-urethral junction with no reconstruction, the bladder is abutting the pubis; (b) Anterior reconstruction group, the bladder is less descended than in the control group after being reconstructed; and (c) Total reconstruction group, the bladder is well suspended above the pubic ramus in comparison with the previous techniques.



studies involving other institutions and possible randomized setting will further define the exact utility and role of this modification.

#### CONFLICT OF INTEREST

None declared.

#### REFERENCES

- 1 Tewari A, Smith JA eds. *Robotic Radical Prostatectomy: Techniques and Issues*. Lippincott Williams & Wilkins Publishers, New York, 2008 (in press)

- 2 **Tewari AK, Bigelow K, Rao S *et al.*** Anatomic Restoration Technique of continence mechanism and preservation of puboprostatic collar: a novel modification to achieve early continence in men undergoing robotic prostatectomy. *Urology* 2007; **69**: 726–31
- 3 **Tewari AK, Rao S, Salamanca J *et al.*** Cancer control and the preservation of neurovascular tissue: how to meet competing goals during robotic radical prostatectomy. *BJU Int* 2008 (in press)
- 4 **Rocco B, Gregori A, Stener S *et al.*** Posterior reconstruction of the rhabdosphincter allows a rapid recovery of continence after transperitoneal videolaparoscopic radical prostatectomy. *Eur Urol* 2007; **51**: 996–1003
- 5 **Rocco F, Carmignani L, Acquati P *et al.*** Restoration of posterior aspect of rhabdosphincter shortens continence time after radical retropubic prostatectomy. *J Urol* 2006; **175**: 2201–6
- 6 **Moinzadeh A, Shunaigat AN, Libertino JA.** Urinary incontinence after radical retropubic prostatectomy: the outcome of a surgical technique. *BJU Int* 2003; **92**: 355–9
- 7 **Takenaka A, Tewari AK, Leung RA *et al.*** Preservation of the puboprostatic collar and puboperineoplasty for early recovery of urinary incontinence after robotic prostatectomy: anatomic basis and preliminary outcomes. *Eur Urol* 2007; **51**: 433–40
- 8 **Tseng TY, Kuebler HR, Cancel QV *et al.*** Prospective health-related quality-of-life assessment in an initial cohort of patients undergoing robotic radical prostatectomy. *Urology* 2006; **68**: 1061–6
- 9 **Tewari A, El-Hakim A, Rao S, Raman JD.** Identification of the retrotrigonal layer as a key anatomical landmark during robotically assisted radical prostatectomy. *BJU Int* 2006; **98**: 829–32
- 10 **Tewari A, Takenaka A, Mtui E *et al.*** The proximal neurovascular plate and the tri-zonal architecture around the prostate gland: importance in the athermal robotic technique of nerve-sparing prostatectomy. *BJU Int* 2006; **98**: 314–23
- 11 **Tewari AK, Rao SR.** Anatomical foundations and surgical manoeuvres for precise identification of the prostatovesical junction during robotic radical prostatectomy. *BJU Int* 2006; **98**: 833–7

**Correspondence:** John A. Libertino, Department of Urology, Lahey Clinic Medical Center, Burlington, MA, USA.  
e-mail: akt2002@med.cornell.edu, jay.jhaveri@gmail.com

**Abbreviations:** RP, radical prostatectomy; (HR)QoL, (health-related) quality of life.